

DOI: 10.21767/2471-299X.1000040

## Eruptive Xanthoma: Combined Hyperlipidemia

Mona A Amin<sup>1\*</sup> and Magdy A Hamed<sup>2</sup><sup>1</sup>Internal Medicine, Cairo University, Egypt<sup>2</sup>Cardiology Department, Cairo University, Egypt

\*Corresponding author: Amin MA, Internal Medicine, Cairo University, Egypt, Tel: 00201001661910; E-mail: monasleman@hotmail.com, monasleman@kasralainy.edu.eg

Received date: November 14, 2016; Accepted date: November 16, 2016; Published date: November 23, 2016

Copyright: © 2016 Amin MA, et al. This is an open-access article distributed under the terms of the Creative Commons Attribution License, which permits unrestricted use, distribution, and reproduction in any medium, provided the original author and source are credited.

Citation: Amin MA, Hamed MA. Eruptive Xanthoma: Combined Hyperlipidemia. Med Clin Rev. 2016, 2:4.

### Image Article

An otherwise healthy 35 years old female not known to be diabetic presented to the outpatient clinic complaining of itchy papular generalized skin eruption, afebrile, no chest or abdominal pain (Figure 1).

**Laboratory investigations:** Total cholesterol 1000 mg/dl triglycerides 10700 mg/dl, HDL 55 mg/dl and fasting blood sugar 234 mg/dl. The patient advised to follow diabetic low fat diet and received gemfibrozil 1200 mg/dl, rusevastatin 20 mg/d, ezetimibe 10 mg/d and glimburide 60 mg/d. One month later, the rash was improved, blood sugar was controlled and the triglyceride decreased to 1370 mg/dl, total cholesterol 334 mg/dl, AST 29 U/L and ALT 19 U/L (Figure 2).

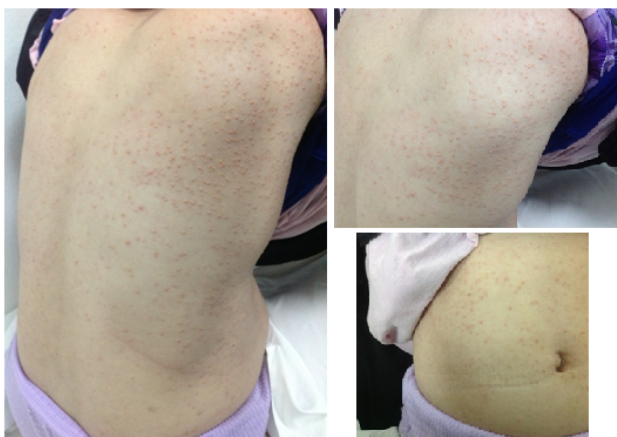


Figure 1: Skin eruption at presentation.

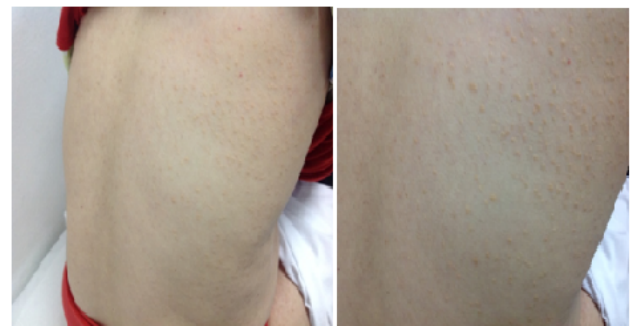

Figure 2: The skin lesion one month later.

### Discussion

High levels of serum triglycerides or uncontrolled diabetes mellitus generally cause eruptive xanthoma [1-3]. This patient discovered to have both markedly elevated lipids and diabetes mellitus and was at high risk for development of eruptive xanthomas.

### References

1. Wolff K, Johnson RA (2009) Fitzpatrick's Color Atlas and Synopsis of Clinical Dermatology (6th edn.) New York: McGraw Hill.
2. Fauci AS, Braunwald E, Kasper DL, Hauser SL (2008) Harrison's Principles of Internal Medicine (17th edn.) New York: McGraw Hill.
3. Durrington P (2003) Dyslipidaemia. Lancet 362: 717-731.