

Still Unknown Cause of Remitting Fever, Still's Disease

Yusuf Eken*

Almere poort, Flevoland, The Netherlands

*Corresponding author: Yusuf Eken, Almere poort, Flevoland, The Netherlands, Tel: 003147958978; E-mail: yusuf.eken@gmail.com

Received date: July 06, 2016; Accepted date: July 22, 2016; Published date: July 29, 2016

Copyright: © 2016 Eken Y. This is an open-access article distributed under the terms of the Creative Commons Attribution License, which permits unrestricted use, distribution, and reproduction in any medium, provided the original author and source are credited.

Abstract

Adult onset Still's disease (AOSD) is a rare disease in adults, in children also known as systemic juvenile idiopathic arthritis. We describe two patients with intermittent fevers without unknown origin. 27 years man and 75 years old woman, who presented with lymphadenopathy and recurrent fevers. There has been used intensive serologic, radiologic, laboratory investigation to exclude infectious diseases and malignancy. All the investigation showed no diagnosis. The clinical disease described for the first time at 11897 by Dr Still is finally diagnosed. Both patients received Anakinra with rapid response in hematologic, biochemical, and cytokine markers with reduction of systemic and local inflammation.

system and by the cytokines involved (e.g., interleukin-1 [IL-1]). Moreover, the blocking of both IL-1 has been shown to be efficacious in the treatment of AOSD. An interleukin-1 (IL-1) antagonism, e.g., with the IL-1 receptor antagonist Anakinra, is the standard of therapy for the exacerbations of acute disease rather than increasing steroid use [5-9].

Case Reports

Case 1

A 27-year-old Caucasian male presented at his first admission with an episode of fever since 4 weeks, diffuse myalgia, sore throat, cold chills and fatigue. The patient was in his usual state of health until 1 month before admission, when he developed fever. He had an 18-pound weight loss over the preceding month. During the fever attacks he had fatigue. He did not report of sick symptoms, arthralgia, abdominal pain, nausea, diarrhoea, cough, dyspnoea, or a rash. He denied oral ulcers, ocular inflammation, photosensitivity, or Raynaud's phenomenon. He reported no pain or stiffness in the neck, low back, or heel. There was no history of recent travel, trauma, or sick contact. The patient's medical history was unremarkable except an episode of fever after a streptococcal infection ten years ago. There was no family history of autoimmune diseases. His medications upon admission were diclofenac 2 dd 100 mg.

Physical examination showed normal vital signs with fever of 40.0°C (104°F). The remainder of the physical examination was unremarkable.

Laboratory test revealed elevated inflammatory markers, including erythrocyte sedimentation rate (ESR; 116 mm/hour), C-reactive protein level (266 mg/liter). A peripheral leucocytosis was present, with a white blood cell count of 22,000/mm³ (normal range 4,500-11,000). WBCs, 90% neutrophils. The serum ferritin level was markedly increased at 5696 ng/ml (normal range 10-200). Urine cultures showed no infection and proteinuria was absent. An infectious disease evaluation was performed and was negative. Serologic study of Rheumatoid factor and anti nuclear antibody were negative.

Antibodies to Sm/RNP, Ro/SSA, and La/SSB; anti cardiolipin antibodies; ant neutrophil cytoplasmic antibodies (ANCA); and anti-cyclic citrullinated peptide antibodies were negative, and creatine phosphokinase was normal. A chest radiograph

Keywords: Systemic JIA; Juvenile idiopathic arthritis; Remitting fever; Autoimmune; Macular or Maculopapular exanthema; Low-grade persistent fevers; Biologicals; IL-1B antagonist; Still's disease

Adult-onset Still's disease (AOSD)

AOSD is a rare systemic inflammatory disease of unknown etiologic that often presents as a fever of unknown origin. Systemic features, such as spiking fever, skin rash, generalized lymphadenopathy, hepatomegaly, splenomegaly, and serositis, was first described by the British paediatrician George F. Still [1] and by Bywaters in 14 patients [2]. The aetiology of AOSD still remains unknown, but overexpression of Th1 cytokines and IL-1 may have a critical role [3]. Pericarditis, pleural effusions, and severe abdominal pain may be present and confound diagnosis [4].

Daily fevers, evanescent rash, arthritis, hyperferritinemia, and liver dysfunction were consistent with AOSD. Hyperferritinemia has a high sensitivity for AOSD (80%) but has a low specificity (40%). The fraction of glycosylated ferritin is higher than with inflammatory conditions. The combination of elevated serum ferritin level and low (20%) fraction of glycosylated ferritin can make the diagnosis of AOSD most likely. In fact AOSD has similarities to auto inflammatory diseases, as exemplified by a central role of the innate immune

was normal. Transesophageal echocardiogram was performed by cardiologist the next day and ruled out endocarditis (no vegetation's, some pericardial fluid).

After being well during 1 year after hospital discharge he complained of since 1 month existing fatigue, diarrhoea, nausea, vomiting, with fever up to 40.3°C (104.54°F). He had recognized dark urine and light coloured defecations. Physical examination at his second admission showed a sick patient with dry mucosa. Blood pressure 123/55, icteric skin, decreased skin turgor. Submandibular, right lateral sternocleidomastoid and right groin lymphadenopathy, all noduli seemed benign. Temperature was 38.9°degrees Celsius (102°F), the pulse rate was 122 beats/minute, and the respiratory rate was 12 breaths/minute. Abdomen is extended with normal with normal bowel sounds, splenomegaly and hepatomegaly 10 cm below the costal arch. His liver function deteriorated and clotting indices were also deranged.

Liver biopsy showed non-specific inflammation (**Figure 1**). Prednisone 60 mg/day was started. The patient's localized rash and fever resolved spontaneously. Liver function showed improvement. He was discharged from our hospital after 3 weeks.

Pathology Report

The biopsy of the liver and lymph nodule biopsy showed no typical sign of malignancy, tuberculosis infection, other infectious cause, sarcoidosis or Kikuchi disease. The only finding at histological examination was nonspecific reactive para cortical hyperplasia. **Figure 1** shows the Liver biopsy from Case 1. There was no necrosis and only slight inflammation. Mediastinal biopsy and lung biopsy of patient B was negative for malignancy.

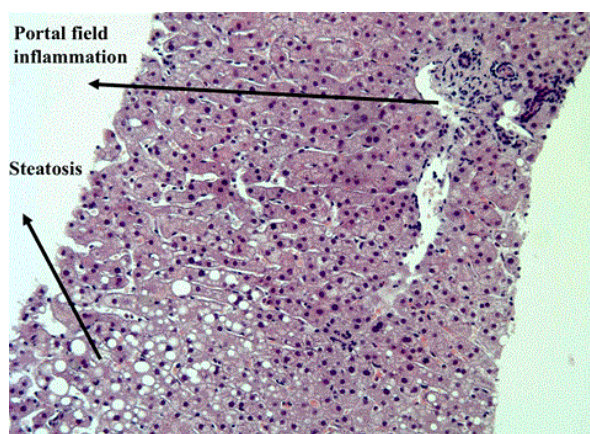


Figure 1: Liver biopsy of Case 1, chronic non specific hepatitis, there was no necrosis and only slight inflammation at portal field.

Case 2

75 years old women presented at our hospital with since months daily fevers between 38 to 39.5°C (100.4°-103.1°F)

with night sweats. Her complaints were of fatigue, dizziness and nausea. Besides the febrile episode she felt well. Attacks of fever occurred sometimes 2 times a day and reached normal level. She lost 10 kilograms in 1 month. She was recent back from holiday in France. During holiday and before she had no contact with domestic animals, no tuberculosis contact, no erythematic rash, no photosensitivity, no Raynaud's phenomenon, no ulcers, no stiffness over the muscles of the legs and arms, no visual or hearing problems. No jaw claudication and no arthritis. There was no family history of autoimmune disease. She had Diabetes Mellitus type II, atrium fibrillation in Medical history and used atenolol/chlortalidon 1 dd 100/25 mg, Metformin 2 dd 500 mg.

Physical examination revealed fully alert, oriented, and lucid sick women. Her vitals sign were as follows. Blood pressure 150/80 mm Hg, Heart beat 76/minute, her oxygen saturation was 95% on room air, and Temperature 37.8°C (100°F), her respiratory rate was 18 breaths/minute unlaboured. Unilateral right sided supraclavicular lymphadenopathy with right thyroid gland nodule. Examination of her heart revealed an irregular tachycardia (atrial flutter on ECG) but no murmurs, rubs, or gallops. The lungs were clear to auscultation. There was no evidence of hepatosplenomegaly, skin rash, focal motor weakness, sensory deficits or arthritis. Laboratory examination showed elevated inflammation levels (CRP 133 mg/L, BSE 48 mm/h). Leucocytes 13.1/nL Neutrophils 11/nL, Calcitonin lightly elevated. No M protein detectable, ACE not elevated. Assays for antinuclear antibodies, antibodies to double stranded DNA, rheumatoid factor, anti-neutrophil cytoplasmic antibodies, anti-phospholipid antibodies, and cryo globulins were negative. The serum C3 and C4 levels were normal. A serum protein electrophoresis test showed normal levels of all immunoglobulin and no monoclonal spike. Blood cultures and a tuberculin test were negative. ECG: Atrium flutter. A complete work-up, including lymph node, bone marrow biopsy, was done to exclude malignancy. Her blood, stool, urine cultures and viral serology were all negative. All serologic examination was negative. Chest radiogram showed cardiomegaly. An ultrasound scan of the abdomen showed no abnormalities. CT thorax showed multiple pathologic mediastinal lymphomas (**Figure 2**).

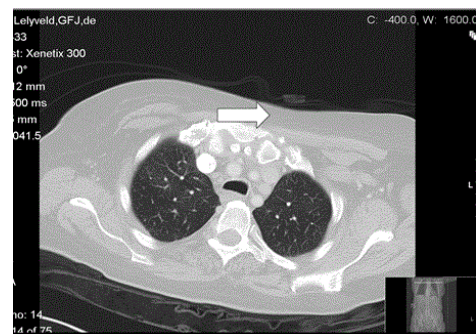


Figure 2: Patient B Ct thorax: multiple lymph nodules increased in size Gantry 0 degrees, FoV: 312 mm, Time 500 ms, Slice 5 mm, 486 mA, 120 kV 14th slice from 75.

Pet scan revealed elevated uptake in multiple pathologic nodule high supraclavicular right and mediastinal. Mediastinal lymph nodule biopsy showed no malignant cells, only non-specific reactive para cortical hyperplasia. Cytological puncture thyroid gland nodule was normal. Bronchoscopy showed no tumor.

During Hospital admission of 7 weeks, she had daily fever attacks with hypotension during febrile episode a 2 periods of 4-5 days without fever. Most of the febrile attacks occurred at night or early in the morning. At the beginning of the hospital stay were the levels of fever higher than compared with the last weeks. She developed during 2nd week pericarditis. Except for the fever attacks she was hemodynamic stable; only during a febrile attack she had hypotension and fatigue. She received Anakinra with clinical remission. There was an initial response without relapse.

General Discussion

These case reports illustrate that we have to be carefully to assume a diagnosis of AOSD. There is no laboratory examination or histological findings that can be diagnostic for, which is purely a clinical diagnosis. Diagnostic criteria for AOSD are described by Yamaguchi et al. (Table 1) [6].

Table 1: Diagnostic criteria for adult onset still's disease.

Diagnostic criteria for adult onset Still's disease	
Yamaguchi's Criteria	Fautrel's Criteria
5 or more criteria are required, of whom 2 or more must be major	4 or more major criteria are required, or 3 major and 2 minor criteria
Major Criteria Fever $>39^{\circ}$, lasting one week or longer Arthralgia or arthritis, lasting 2 weeks or longer Typical rash Leukocytosis $>10,000/\text{mm}^3$ with $>80\%$ polymorphonuclear cells	Major Criteria Spiking fever $\geq 39^{\circ}$ Arthralgia Transient erythema Pharyngitis Polymorphonuclear cells $\leq 80\%$ Glycosylated ferritin $\leq 20\%$
Minor Criteria Sore throat Recent development of significant lymphadenopathy Hepatomegaly or Splenomegaly Abnormal liver function tests Negative tests for antinuclear antibody (IF) and Rheumatoid factor (IgM)	Minor Criteria Maculopapular rash Leukocytosis $\geq 10,000/\text{mm}^3$
Exclusion Criteria Infections Malignancies (Mainly Malignant Lymphoma) Other Rheumatic Diseases (mainly Systemic vasculitides)	-

Note: Several diagnostic criteria have been proposed, Yamaguchi's and Fautrel's criteria being the most employed

Exclusion of malignancies of the lymph reticular system is very important in establishing the diagnosis. Our patient's intermittent fevers to greater than 38.3°C for more than 3 weeks meet the classic definition of fever of unknown origin (FUO). Reviews of large case series of FUO suggest that a primary inflammatory process is responsible for the fever in 22% of cases. Infection and malignancy account for 16% and 7%, respectively, and miscellaneous conditions account for an additional 16%. More than half of cases of FUO have remained without diagnoses in some series.

Case 1 met the 5 acquired criteria from which 2 major criteria for the Diagnosis of adult onset Still's disease according to Yamaguchi et al. (Table 1) [6]. In Case 1 presented with 3 major criteria (spiking fever, pharyngitis, glycosylated ferritin $<20\%$) and 3 minor criteria (maculopapular exanthema, leucocytosis of $22,000/\text{mm}^3$ WBC 90% neutrophils, abnormal liver enzyme tests). Case 2 had two major criteria according to Yamaguchi et al. (spiking fever $>3^{\circ}\text{C}$, had Leucocytosis $13,100$ with 84% consisting from neutrophils). Case 2 had 2 minor criteria namely negative serologic tests for anti-nuclear antibody and rheumatoid factor, Recently developed Lymphadenopathy. Case 2 had a few nodules supraclavicular. After radiological investigation there were multiple mediastinal nodules in Case 2. Malignancy especially Lymphoma and leukaemia are excluded by biopsy. High fever, rash, liver dysfunction, ferritin can be consistent with sepsis. Endocarditis should also be considered. Both patients thought to have an infection as a most probable cause of fever. Serologic examination revealed no infectious cause. In both patients Cardiologist excluded an endocarditis. Case 2 had the 4 acquired major criteria according Fautrel (Table 1). Spiking fever longer than 2 weeks, Polymorphonuclear cells $>80\%$, elevated ferritin from which glycosylated ferritin $<20\%$ and erythema. Case 2 had one minor criteria according to Fautrel namely leucocytosis. Both cases met the acquired criteria for diagnosis of AOSD. Yamaguchi criteria has been used for diagnosis of AOSD in case 1, Fautrel criteria for case 2.

Treatment of systemic juvenile idiopathic arthritis is similar to treatment of AOSD [6]. In the clinical department of affiliated Academic Centers is already frequently used as treatment treatment for AOSD. For the evidence that exists of the use of antagonists of IL-1B in the literature see references [6-10]. Role of IL1 in juvenile rheumatoid arthritis is already proven [11].

In case 1 the first 7 years after onset of AOSD corticosteroids and at fourth year from onset of AOSD is modifying anti rheumatoid drug (DMARD) Methotrexate (MTX) added with good response. Only after years and two severe relapses of AOSD by an unresponsive disease course treatment with DMARD MTX and corticosteroid is switched to biological IL-1B antagonist. Two months after start Anakinra 1 dd 100 mg as monotherapy, systemic inflammation and fever attacks improved. The liver function and inflammatory parameters are

normalized. Since start of the treatment with Anakinra no complaints or relapse of AOSD.

Case 2 did not receive corticosteroids as first choice because of presence of dysregulated diabetes mellitus type II. The use of corticosteroids have an unavoidable side effect on blood glucose levels on patients with Diabetes Mellitus that is dysregulated due to AOSD episode. Methotrexate is also bypassed by this patient. She had a 2 months long admission and effect of Methotrexate take weeks after intake. To shorten her quality of life as soon as possible, at second month of admission is the treatment with IL1B antagonist started. In other patients especially adult ones, the first choice of treatment remains corticosteroids and DMARDs.

Final Diagnosis

Adult Onset Still's Disease.

References

1. Still GF (1897) On a form of chronic joint disease in children. *Med Chir Trans* 80: 47-59.
2. Bywaters EGL (1971) Still's disease in an adult. *Ann Rheum Dis* 30: 121-133.
3. Efthimiou P, Paik PK, Bielory L (2006) Diagnosis and management of adult onset Still's disease. *Ann Rheum Dis* 65: 564-572.
4. Aptekar RG, Deckere JL, Bujak JS, Wolff MS (1973) Adult onset juvenile rheumatoid arthritis. *Arthritis Rheum* 16: 715-718.
5. Pascual V, Allantaz F, Arce E, Punaro M, Banchereau J (2005) Role of interleukin-1 (IL-1) in the pathogenesis of systemic onset juvenile idiopathic arthritis and clinical response to IL-1 blockade. *Journal of Experimental Medicine* 201: 1479-1486.
6. Yamaguchi M, Ohta A, Tsunematsu T, Kasukawa R, Mizushima Y, et al. (1992) Diagnostic criteria for adult onset Still's disease (AOSD). *J Rheumatol* 19: 424-430.
7. Franchini S, Dagna L, Salvo F, Aiello P, Baldissera E, et al. (2010) Efficacy of traditional and biologic agents in different clinical phenotypes of AOSD. *Arthritis Rheum* 62: 2530-2535.
8. Fitzgerald AA (2005) Treatment of adult Still's disease. *Arthritis Rheum* 52: 1794.
9. Irigoyen (2004) Treatment of systemic onset juvenile arthritis with anakinra. *Arthritis Rheum* 50: S437.
10. Lequerre T, Quartier P, Rosellini D, Alaoui F, De Bandt M, et al. (2008) Interleukin-1 receptor antagonist (anakinra) treatment in patients with systemic onset juvenile idiopathic arthritis or adult onset Still disease: preliminary experience in France. *Ann Rheum Dis* 67: 302.
11. Yilmaz M, Kendirli SG, Altintas D, Bingöl G, Antmen B, et al. (2001) Cytokine Levels in Serum of Patients with Juvenile Rheumatoid Arthritis. *Clin Rheumatol* 20: 30-35.